

Inherited epidermolysis bullosa: Updated recommendations on diagnosis and classification

Jo-David Fine, MD, MPH, FRCP,^{a,b} Leena Bruckner-Tuderman, MD, PhD,^c Robin A. J. Eady, DSc, FRCP, FMedSci,^d Eugene A. Bauer, MD,^e Johann W. Bauer, MD,^f Cristina Has, MD,^c Adrian Heagerty, MD, FRCP,^g Helmut Hintner, MD,^f Alain Hovnanian, MD, PhD,^h Marcel F. Jonkman, MD, PhD,ⁱ Irene Leigh, CBE, DSc, FRCP, FRSE, FMedSci,^j M. Peter Marinkovich, MD,^{e,k} Anna E. Martinez, FRCPC,^l John A. McGrath, MD, FRCP, FMedSci,^d Jemima E. Mellerio, MD, FRCP,^{d,l} Celia Moss, DM, FRCP, MRCPC,^m Dedee F. Murrell, MD, FACD,ⁿ Hiroshi Shimizu, MD, PhD,^o Jouni Uitto, MD, PhD,^p David Woodley, MD,^q and Giovanna Zambruno, MD^r
Nashville, Tennessee; Freiburg, Germany; London and Birmingham, England; Stanford, Palo Alto, and Los Angeles, California; Salzburg, Austria; Toulouse, France; Groningen, The Netherlands; Dundee, Scotland; Sydney, Australia; Sapporo, Japan; Philadelphia, Pennsylvania; and Rome, Italy

Background: Several new targeted genes and clinical subtypes have been identified since publication in 2008 of the report of the last international consensus meeting on diagnosis and classification of epidermolysis bullosa (EB). As a correlate, new clinical manifestations have been seen in several subtypes previously described.

Objective: We sought to arrive at an updated consensus on the classification of EB subtypes, based on newer data, both clinical and molecular.

Results: In this latest consensus report, we introduce a new approach to classification (“onion skinning”) that takes into account sequentially the major EB type present (based on identification of the level of skin cleavage), phenotypic characteristics (distribution and severity of disease activity; specific extracutaneous features; other), mode of inheritance, targeted protein and its relative expression in skin, gene involved and type(s) of mutation present, and—when possible—specific mutation(s) and their location(s).

Limitations: This classification scheme critically takes into account all published data through June 2013. Further modifications are likely in the future, as more is learned about this group of diseases.

Conclusion: The proposed classification scheme should be of value both to clinicians and researchers, emphasizing both clinical and molecular features of each EB subtype, and has sufficient flexibility incorporated in its structure to permit further modifications in the future. (*J Am Acad Dermatol* 2014;70:1103-26.)

Key words: classification; diagnosis; electron microscopy; epidermolysis bullosa; gene; genetics; monoclonal antibodies.

From the Vanderbilt University School of Medicine, Nashville^a; National Epidermolysis Bullosa Registry, Nashville^b; University Medical Center Freiburg^c; St John’s Institute of Dermatology, King’s College London and Guy’s and St Thomas’ Hospital National Health Service Foundation Trust^d; Stanford University School of Medicine^e; Paracelsus Private Medical University, Salzburg^f; Heart of England Foundation Trust, Birmingham^g; INSERM and Department of Genetics, Toulouse^h; University Medical Center Groningen, University of Groningenⁱ; University of Dundee^j; Dermatology Service, Palo Alto Veterans Affairs Medical Center^k; Great Ormond Street Hospital for Children National Health Service Foundation Trust, London^l; Birmingham Children’s Hospital and University of Birmingham^m; St George Hospital and University of New South Wales, Sydneyⁿ; Hokkaido University School of Medicine, Sapporo^o; Thomas Jefferson University, Philadelphia^p; University of Southern California, Los Angeles^q; and Istituto Dermopatico dell’Immacolata, IDI-IRCCS, Rome.^r

Funding sources: None. (Although the authors have acknowledged in other unrelated publications their extramural support for their own epidermolysis bullosa–related research programs, none of these has provided funding for the Consensus Conference or the generation of this report.)

Conflicts of interest: None declared.

Accepted for publication January 25, 2014.

Reprints not available from the authors.

Correspondence to: Jo-David Fine, MD, MPH, FRCP, Division of Dermatology, c/o Vanderbilt Health One Hundred Oaks, Dermatology Suite 26300, 719 Thompson Ln, Nashville, TN 37204. E-mail: Jo-David.Fine@vanderbilt.edu.

Published online March 31, 2014.

0190-9622/\$36.00

© 2014 by the American Academy of Dermatology, Inc.

<http://dx.doi.org/10.1016/j.jaad.2014.01.903>

Each of the many subtypes of inherited epidermolysis bullosa (EB) is currently defined by its mode of transmission and a combination of phenotypic, ultrastructural, immunohistochemical, and molecular findings.¹ Much has been learned about the natural history and etiopathogenesis of EB since this disease was first formally classified, based on electron microscopic features described in 1962,² as a result of the application of epidemiology, cell biology, immunology, and molecular biology to the study of large numbers of clinically well-characterized patients.

Four international consensus meetings on its diagnosis and classification have been held since 1988, the last in Vienna, Austria, in 2007.¹ Since then, several new phenotypes and causative genes have been identified. In June 2013 a number of leading EB experts met in London, United Kingdom, to review the collective data on this disease and to reformulate the means whereby patients with EB can be subclassified, with increasing focus on the molecular origin of each subtype whenever possible.

MAJOR EB TYPES

We recommend that the currently used names for the 4 major EB types—EB simplex (EBS), junctional EB (JEB), dystrophic EB (DEB), and Kindler—be retained, so as to maintain continuity with decades of clinical and basic scientific literature and to prevent any confusion or ambiguity arising among patients; EB support organizations; medical, nursing, and other clinical colleagues; governmental agencies; and third-party insurers. Changing those names would add little or no value and might prove counterproductive to the diagnosis and care of these patients.

EBS encompasses all subtypes of EB having mechanical fragility and blistering confined to the epidermis. When the classification system was last revised, EBS was further separated into suprabasal and basal subgroups, based on the histopathologic site of cleavage within the epidermis.¹ In the past EBS was referred to by some as “epidermolytic” although this term is inaccurate, because cellular lysis is not a primary feature of any type or subtype of

EB. JEB includes all subtypes of EB in which blisters develop within the mid portion or junction, the so-called lamina lucida, of the skin basement membrane zone (BMZ). DEB (in the past referred to occasionally as “dermolytic” EB) includes all EB subtypes in which blistering occurs within the uppermost dermis (ie, just beneath the lamina densa of the skin BMZ).

Finally, Kindler syndrome, which was added to the EB classification in 2008, describes a specific entity that is characterized by the presence of clinical phenotypic features unique among EB (most notably photosensitivity) and blistering that arises in multiple levels within and/or beneath the BMZ, rather than within a discrete plane, as occurs in all other EB types.

DIAGNOSTIC TESTING IN EB

Diagnostic testing and classification in EB begin with the identification of the level of skin cleavage via immunofluorescence antigen mapping (IFM) and/or transmission electron microscopy on preferably newly

induced blisters. The use of monoclonal antibodies directed against components of the skin BMZ and epidermal antigens can further facilitate subclassification, because skin samples from most of the EB subtypes vary in the intensity of antigen staining (if even present) of specific structural proteins, corresponding to the presence of a mutation within its associated gene. Details of the immunohistochemical and ultrastructural findings in each of the major EB subtypes may be found in our last consensus report, published in 2008.¹

Once the level of skin cleavage and the antigen staining profile have been determined, pursuit of mutational analysis is recommended, if available and affordable, because this will permit the most precise subclassification. The latter information will become critical for genetic counseling in the future, if and when molecular treatments become a reality. For now, molecular fingerprinting provides the most precise way of ascertaining mode of transmission, enabling the clinician to accurately perform genetic counseling. Reliance solely on mutational findings for accurate clinical prognostication, however, must

CAPSULE SUMMARY

- Many new genes and clinical phenotypes of inherited epidermolysis bullosa have been characterized since the last international consensus meeting on diagnosis and classification was published in 2008.
- A new classification system (“onion skin” approach) has been created that sequentially takes into account the epidermolysis bullosa type, mode of inheritance, phenotype, immunofluorescence antigen mapping findings, and mutation(s) present in each patient.
- Detailed summaries on the typical findings in each recognized epidermolysis bullosa subtype are provided for use by clinicians and researchers.

Abbreviations used:

BMZ:	basement membrane zone
BP:	bullous pemphigoid
DDEB:	dominant dystrophic epidermolysis bullosa
DEB:	dystrophic epidermolysis bullosa
EB:	epidermolysis bullosa
EBS:	epidermolysis bullosa simplex
IFM:	immunofluorescence antigen mapping
JEB:	junctional epidermolysis bullosa
RDEB:	recessive dystrophic epidermolysis bullosa

be done with care, because considerable variation may exist in disease severity and the natural history of patients within even a single EB subtype or

kindred, because of the influence of environmental and/or modifying genetic factors.

“ONION SKIN” APPROACH TO CLASSIFICATION

Initial attempts at the classification of patients with EB at the bedside are based on personal and family history and the presence or absence of specific clinical features, both cutaneous and extracutaneous. Only later, once more sophisticated laboratory testing has been performed, is it possible to subclassify these patients more accurately. As with any other disease, a physician sees, listens to, and examines a patient suspected of having EB; generates a differential diagnosis; and then pursues increasingly sophisticated laboratory tests as the needs demand. This approach

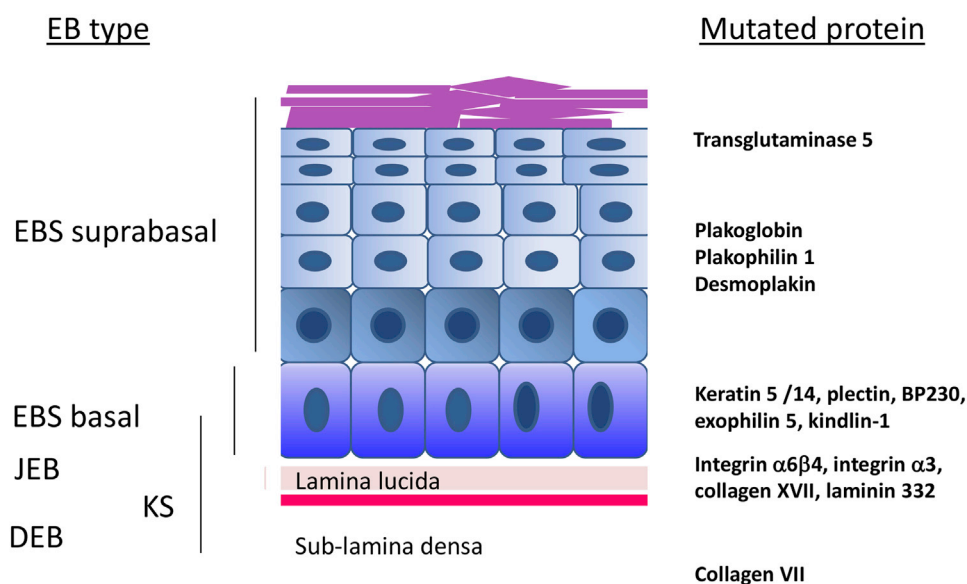


Fig 1. A schematic representation of the epidermis, the skin basement membrane zone, the location of specific proteins pertinent to the pathogenesis of epidermolysis bullosa (EB), and the level in which blisters develop in different EB types. The scheme depicts the cell layers of the epidermis, the basal keratinocytes, and above them the suprabasal keratinocyte layers (spinous and granular layers), which are covered by the horny layer (*pink*). The epidermis is attached to the dermis by the bilayered basement membrane consisting of lamina lucida and lamina densa (*red bar*). On the *left*, the level of blister formation is indicated. In EB simplex (EBS) suprabasal, the blisters form within the middle/upper epidermal layers, depending on which protein is mutated. In EBS basal, the cleavage plain is within the basal keratinocytes. In junctional EB (JEB), the separation takes place within the lamina lucida, and in dystrophic EB (DEB), within the sublamina densa region within the uppermost dermis. In Kindler syndrome (KS), cleavage can occur within the basal keratinocytes, at the level of the lamina lucida or below the lamina densa. On the *right*, the localizations of the relevant mutated proteins are indicated. Transglutaminase 5 is present in the uppermost cell layers of the epidermis. Plakoglobin and desmoplakin are desmosomal proteins that are panepidermal, compared with plakophilin 1, which is expressed mainly in the suprabasal epidermis. Keratins 5 and 14, plectin, BP230, exophilin 5 and kindlin-1 are found mainly within the basal keratinocytes. Integrin $\alpha6\beta4$, integrin $\alpha3$, and collagen XVII are transmembrane proteins with extracellular domains emanating from the plasma membrane of the basal keratinocytes into the lamina lucida. Laminin 332 is a lamina lucida protein and collagen VII, the major component of the anchoring fibrils, is found in the sublamina densa region.

Table I. The major epidermolysis bullosa types and subtypes

Level of skin cleavage	Major EB type	Major EB subtypes	Targeted protein(s)
Intraepidermal	EBS	Suprabasal EBS	Transglutaminase 5; plakophilin 1; desmoplakin; plakoglobin
		Basal EBS	Keratins 5 and 14; plectin; exophilin 5 (Slac2-b); bullous pemphigoid antigen 1
Intralamina lucida	JEB	JEB, generalized	Laminin-332, collagen XVII; $\alpha6\beta4$ integrin; $\alpha3$ integrin subunit
Sublamina densa	DEB	JEB, localized	Collagen XVII; laminin-332; $\alpha6\beta4$ integrin
		DDEB	Collagen VII
		RDEB	Collagen VII
Mixed	Kindler syndrome	—	Fermitin family homolog 1 (kindlin-1)

DDEB, Dominant dystrophic epidermolysis bullosa; DEB, dystrophic epidermolysis bullosa; EB, epidermolysis bullosa; EBS, epidermolysis bullosa simplex; JEB, junctional epidermolysis bullosa; RDEB, recessive dystrophic epidermolysis bullosa.

Table II. Morphologic and molecular features of the major epidermolysis bullosa simplex subtypes⁶⁻¹⁹

Major EBS subtype	Usual level of blister formation	Protein affected and pattern of IF staining	Mutated gene(s)
EBS, suprabasal* [†]	Suprabasal epidermis [§]	Transglutaminase 5: normal, reduced, or absent Desmoplakin (or its C-terminus): absent or reduced Plakoglobin: reduced or absent Plakophilin 1: reduced or absent	<i>TGM5</i> ^{10,15} <i>DSP</i> ¹¹⁻¹³ <i>JUP</i> ¹⁴ <i>PKP1</i> ¹⁶
EBS, basal [‡]	Basal epidermis	Keratin 5 or keratin 14: usually normal Exophilin 5 (Slac2-b): absent Plectin: absent or reduced Bullous pemphigoid antigen-1 (BPAG1; BP230) absent	<i>KRT5</i> , <i>KRT14</i> <i>EXPH5</i> ^{17,18} <i>PLEC</i> <i>DST</i> ¹⁸

EBS, Epidermolysis bullosa simplex; IF, immunofluorescence.

*Suprabasal EBS encompasses all EBS subtypes in which blister formation arises above the level of the basal keratinocyte.

[†]Biallelic homozygous nonsense mutations in the desmocollin-3 gene have been associated with hereditary hypotrichosis and recurrent scalp vesicles.

[‡]*KRT6C* mutations cause focal palmoplantar keratoderma with minimal nail changes and skin blistering.⁹

[§]Acral peeling skin syndrome, which arises subcorneally, may also be caused by mutations in the genes encoding cystatin A (*CSTA*),^{6,7} N-acetylgalactosamine-4-O-sulfotransferase (*CHST8*),⁸ or comeodesmosin (*CDSN*) (although the latter 2 are associated with generalized peeling skin).

suggests a simple yet elegant means of standardizing nomenclature and subclassification of EB, given recent advances in our understanding of this group of diseases at the molecular level and taken in context with clinical findings that have been observed in robust, well-characterized patient cohorts.

Analogous to peeling an onion, we propose that the classification and subclassification of patients with EB begin with their separation into 1 of the 4 major EB groups, based on the level (intraepidermal [EBS]; within [JEB] or beneath [DEB] the skin BMZ; or mixed pattern [Kindler syndrome]) within which blisters develop (Table I and Fig 1). The next level of subclassification takes into account the clinical phenotypic features present in a given patient, most notably the distribution (localized vs generalized) and relative severity of cutaneous and extracutaneous disease involvement. As a correlate, the presence of diagnostically useful skin findings (eg, exuberant granulation tissue; mottled pigmentation;

pseudosyndactyly; other) may permit further subclassification at this level. Each patient then can be further subclassified on the basis of the mode of transmission and, if identifiable, by the specific gene involved, the latter initially determined by means of immunohistochemical techniques (IFM, using EB-pertinent monoclonal antibodies) and later by mutation analysis (Tables II to VII). In some clinical settings, some EB investigators prefer to pursue molecular screening without first obtaining IFM results. In the evaluation of a patient with clinically obvious severe generalized recessive DEB (RDEB), this is reasonable and cost-effective. This is not the course taken by most investigators, however, for EB subtypes in which multiple genes may cause identical phenotypes (ie, severe generalized JEB), given the current cost and time involved in screening multiple genes. In the future, marked reduction in the cost of performing massive parallel sequencing of EB targeted genes may argue for more immediate

Table III. Epidermolysis bullosa simplex clinical subtypes

EBS	Major types	EBS subtypes	Targeted protein(s)
Suprabasal		Acral peeling skin syndrome (APSS)*	Transglutaminase 5
		EBS superficialis (EBSS)*	Unknown [†]
		Acantholytic EBS (EBS-acanth)*	Desmoplakin, plakoglobin
		Skin fragility syndromes*	
		-Desmoplakin deficiency (EBS-desmoplakin; skin fragility-woolly hair syndrome)*	Desmoplakin
		-Plakoglobin deficiency (EBS-plakoglobin; skin fragility-plakoglobin deficiency)*	Plakoglobin
		-Plakophilin deficiency (EBS-plakophilin; skin fragility-ectodermal dysplasia syndrome)*	Plakophilin 1
Basal		EBS, localized (EBS-loc)	K5; K14
		EBS, generalized severe (EBS-gen sev)	K5; K14
		EBS, generalized intermediate (EBS-gen intermed)	K5; K14
		EBS with mottled pigmentation (EBS-MP)*	K5
		EBS, migratory circinate (EBS-migr)*	K5
		EBS, autosomal recessive K14 (EBS-AR K14)*	K14
		EBS with muscular dystrophy (EBS-MD)	Plectin
		EBS with pyloric atresia (EBS-PA)*	Plectin; $\alpha6\beta4$ integrin
		EBS-Ogna (EBS-Og)*	Plectin
		EBS, autosomal recessive—BP230 deficiency (EBS-AR BP230)*	Bullous pemphigoid antigen-1 (BP230)
EBS, autosomal recessive—exophilin 5 deficiency (EBS-AR exophilin 5)*	Exophilin 5		

EBS, Epidermolysis bullosa simplex.

*Rare variants.

[†]No mutations detected in genes encoding for transglutaminase 5 and collagen type VII in the original patient who was characterized (JA McGrath, unpublished data, 2013).

molecular testing. In the absence of molecular data, in those rare patients on whom the level of skin cleavage is ascertained solely by electron microscopy, pertinent ultrastructural features (eg, alterations in structure and/or numbers of anchoring fibrils or hemidesmosomes, or the presence of abnormal keratin filament aggregates) would be used in classification of the patient.

Schematically, this progressive approach may be summarized as: major EB type → phenotype (severity and distribution) → mode of transmission → ultrastructural site of cleavage and associated findings → protein involved (with or without specific IFM findings listed) → gene involved and mutational type → specific mutation present.

A contracted version of the onion skin classification scheme (eg, omitting the listing in the patient's classification of the mode of transmission and the targeted protein, once the type of mutation[s] present has or have been determined) might be used in routine clinical settings, based on the particular needs of the clinician. It is also understood that there may be considerable overlap among the severity grades of mild, intermediate, and severe, and that some patients with "mild" subtypes of EB may be extremely disabled despite relatively limited areas of skin involvement. These terms are used to define the usual degree of severity that has been seen within

each of the major and minor EB subtypes, when large cohorts have been studied.

Table VIII compares this proposed nomenclature for several major EB subtypes with that adopted in 2008.

The following clinical scenarios illustrate how this might be done in individual patients.

1. A patient with intraepidermal blister formation, blistering confined to the palms and soles, and a family history consistent with autosomal dominant transmission would initially be classified as having localized EBS. Once mutational confirmation is completed, the final diagnosis, using the onion skin method, would be: EBS, localized, *KRT5* mutation (missense mutation).
2. A child with generalized blistering and skin cleavage within the lamina lucida of the BMZ would be classified as having JEB, generalized. In the presence of specific phenotypic findings (eg, marked growth retardation, severe anemia, exuberant granulation tissue, upper airway involvement, and severe intraoral disease) and IFM demonstration of absent staining of laminin-332, the diagnosis would be: JEB, severe generalized, laminin-332 negative. Once mutational confirmation is available, final subclassification would become: JEB, generalized severe, laminin-332

Table IV. Morphologic and molecular features of the major junctional epidermolysis bullosa subtypes

Major JEB subtype	Usual level of blister formation	Targeted protein(s)	Protein staining pattern	Mutated gene(s)	
JEB, generalized	JEB, generalized severe (JEB-gen sev)	Intra-LL	Laminin-332	Absent or markedly reduced	<i>LAMA3, LAMB3, LAMC2</i>
	JEB, generalized intermediate (JEB-gen intermed)	Intra-LL	Laminin-332	Reduced	<i>LAMA3, LAMB3, LAMC2</i>
	JEB with pyloric atresia (JEB-PA)*†	Intra-LL	Collagen XVII Integrin $\alpha6\beta4$	Absent or reduced Absent or markedly reduced	<i>COL17A1</i> <i>ITGB4, ITGA6</i>
	JEB, late onset (JEB-LO)*	Intra-LL or no apparent blistering	Collagen XVII	Reduced or positive but with abnormal pattern	<i>COL17A1</i>
	JEB with respiratory and renal involvement (JEB-RR)*	Intra-LL	Integrin $\alpha3$ subunit	Absent or normal	<i>ITGA3</i>
JEB, localized	JEB, localized (JEB-loc)‡	Intra-LL	Collagen XVII Integrin $\alpha6\beta4$ Laminin-332	Absent or reduced Reduced Reduced	<i>COL17A1</i> <i>ITGB4</i> <i>LAMA3, LAMB3, LAMC2</i>
	JEB, inversa (JEB-inv; JEB-I)*	Intra-LL	Laminin-332	Reduced	<i>LAMA3, LAMB3, LAMC2</i>
	JEB-LOC syndrome*	No blistering	Laminin-332, isoform $\alpha3$ chain	Normal	<i>LAMA3A</i> §

JEB, Junctional epidermolysis bullosa; LL, lamina lucida; LOC, laryngo-onycho-cutaneous.

*Rare variants.

†A few patients with JEB and ITGB4 mutations have been reported who had generalized skin involvement and a fatal course but lacked pyloric atresia. In one of these kindreds, an affected sibling with the same mutation and blistering also had pyloric atresia.

‡Not all patients with JEB, localized, having laminin-332 mutations have an inversa phenotype (Kiritzi and Has, unpublished data, 2013).

§Compound heterozygous mutations in *LAMA3* and its isoform $\alpha3a$ (*LAMA3A*) may occur in some patients who display clinical features of both JEB, generalized intermediate, and JEB-LOC syndrome.

Table V. Morphologic and molecular features of dystrophic epidermolysis bullosa subtypes

DEB subtype	Level of blister formation	Protein affect and pattern of IF staining	Mutated gene(s)
DDEB (all subtypes except bullous dermolysis of the newborn)	Dermal (sublamina densa)	Collagen VII: normal or reduced	<i>COL7A1</i>
DDEB and RDEB, bullous dermolysis of the newborn	Dermal (sublamina densa)	Collagen VII: granular staining within basal keratinocytes and reduced/absent staining along the DEJ during active disease; normal DEJ staining when older and if becomes clinically inactive	<i>COL7A1</i>
RDEB, generalized severe	Dermal (sublamina densa)	Collagen VII: absent or markedly reduced	<i>COL7A1</i>
RDEB, generalized intermediate	Dermal (sublamina densa)	Collagen VII: reduced	<i>COL7A1</i>
RDEB, localized	Dermal (sublamina densa)	Collagen VII: reduced or normal	<i>COL7A1</i>
RDEB, all other subtypes	Dermal (sublamina densa)	Collagen VII: reduced	<i>COL7A1</i>

DDEB, Dominant dystrophic epidermolysis bullosa; DEB, dystrophic epidermolysis bullosa; DEJ, dermoepidermal junction; IF, immunofluorescence; RDEB, recessive dystrophic epidermolysis bullosa.

absent, *LAMA3* mutations, mutation types specified (eg, nonsense/nonsense mutations).

3. An adult with generalized blistering and sublamina densa blistering would be initially classified as having generalized DEB. A history of identical disease in 2 preceding generations suggests

dominant DEB. Final subclassification might be: dominant DEB, generalized, *COL7A1* mutation, mutation type specified (ie, missense mutation).

4. A child with severe generalized blistering and scarring, sublamina densa blistering, growth retardation, severe anemia, marked digital web

Table VI. Dystrophic epidermolysis bullosa clinical subtypes

DEB, major subtypes	All subtypes	Targeted protein(s)
DDEB	DDEB, generalized (DDEB-gen)	Collagen VII
	DDEB, acral (DDEB-ac)*	
	DDEB, pretibial (DDEB-pt)*	
	DDEB, pruriginosa (DDEB-pr)*	
	DDEB, nails only (DDEB-na)*	
	DDEB, bullous dermolysis of the newborn (DDEB-BDN)*	
RDEB	RDEB, generalized severe (RDEB-gen sev)	Collagen VII
	RDEB, generalized intermediate (RDEB-gen intermed)	Collagen VII
	RDEB, inversa (RDEB-inv; RDEB-l)	
	RDEB, localized (RDEB-loc)*	
	RDEB, pretibial (RDEB-pt)*	
	RDEB, pruriginosa (RDEB-pr)*	
	RDEB, centripetalis (RDEB-ce)*	
	RDEB, bullous dermolysis of the newborn (RDEB-BDN)*	

DDEB, Dominant dystrophic epidermolysis bullosa; DEB, dystrophic epidermolysis bullosa; RDEB, recessive dystrophic epidermolysis bullosa.

*Rare variants.

formation, esophageal strictures, and lack of a positive family history would initially be classified as having RDEB, generalized severe. After completion of IFM and mutational analysis, final subclassification would be: RDEB generalized severe, collagen VII absent, *COL7A1* nonsense/nonsense mutations.

- A patient clinically meeting the diagnosis of inverse RDEB would eventually be subclassified as: RDEB inversa, collagen VII reduced, *COL7A1* mutations (ie, nonsense/missense mutation).

It should be emphasized that lack of knowledge as to the specific type(s) of mutation present does not preclude classification, because the onion skin approach reveals only as many layers as can be elucidated in a given patient. For example, a newborn with JEB having decreased laminin-332 staining and yet lacking informative phenotypic features may be best classified as JEB generalized, decreased laminin-332 staining, until additional data become available. Such patients in the past were classified by some experts as having generalized JEB, indeterminate subtype, until further clinical or laboratory findings permitted more accurate subclassification. Similarly, before mutational analysis, a severely affected autosomal recessive case with generalized skin and extracutaneous disease activity and absent staining of collagen VII in the skin would

be classified as: RDEB generalized severe, collagen VII absent. It should be noted that although inclusion of the specific mutational type and site of mutation would be truly definitive, issues related to patient privacy may prevent use of such data in any format, most notably publication, that can be accessed by anyone other than the patient, his or her physician, and the diagnostic laboratory.

Finally, it is understood that it may be cumbersome to use complete naming in our routine interactions with patients and their referring physicians. A severely affected patient with proven nonsense/nonsense mutations in *COL7A1* will still be referred to as having RDEB generalized severe. The more precise onion skin designation of each patient, however, provides documentation to support such a diagnosis and will be invaluable for clinical trials and basic research, and the publication of such results.

ELIMINATION OF EPONYMS AND OTHER PROPOSED NAME CHANGES

Since the first description of EB in 1886, as new EB phenotypes were recognized it became a common practice to attach the name(s) of the clinician(s) who first reported them. A similar tradition has existed in many medical and surgical specialties in the naming of rare syndromes and surgical procedures. Unfortunately, although some eponyms immediately bring to mind specific phenotypic features, and their use honors those who astutely first recognized these conditions, eponyms have no immediate descriptive value, making their comparison with other related entities difficult for clinicians who are not experts on a given group of diseases. As a result, many authorities and journals now discourage the continued use of eponyms.

We recommended in previous consensus reports that several eponyms, to include Weber-Cockayne, Koebner, Hallopeau-Siemens, and Bart, be eliminated and substituted with descriptive terms (EBS localized, EBS generalized other, RDEB generalized severe, and EB with congenital absence of skin, respectively). The eponyms Cockayne-Touraine and Pasini were previously dropped from the subclassification of dominant DEB, because clinical and molecular data increasingly suggested that such a separation was artificial. In an effort to be consistent, we recommend that all remaining EB eponyms be eliminated. The only exceptions are Kindler syndrome and EBS-Ogna, for lack of any better suggested names. JEB Herlitz will be renamed as JEB generalized severe and EBS Dowling-Meara will become EBS generalized severe. Table IX lists old and new names for all EB subtypes previously associated with eponyms. We have also listed within

Table VII. Types of mutations known in the major epidermolysis bullosa subtypes

EB type	EB subtype	Mutated genes	Types of mutations known
EBS	EBS, suprabasal	<i>TGM5</i>	MS, Del, Indels
		<i>DSP</i>	NS, Del, MS
		<i>PKP1</i>	Spl, NS, Del, Indels, Ins
		<i>JUP</i>	NS, Spl
		<i>KRT5</i>	MS, Del, Spl, NS, Indels
	EBS, basal	<i>KRT14</i>	MS, Del, NS, Spl, Indels, Ins
		<i>EXPH5</i>	Del, NS, Ins
		<i>PLEC</i>	NS, Del, Ins, Spl, Indels, MS
		<i>DST</i>	NS
JEB	JEB, severe generalized	<i>LAMA3</i>	NS, Del, Spl
		<i>LAMB3</i>	NS, Del, Spl, Ins
		<i>LAMC2</i>	NS, Del, Spl, Indels
	JEB, generalized/localized	<i>LAMA3</i>	MS, NS, Spl, Ins
		<i>LAMB3</i>	MS, NS, Spl, Del, Ins, Indels
		<i>LAMC2</i>	NS, Del, Indels, Ins, Spl
		<i>COL17A1</i>	NS, Del, Spl, Ins, MS
		<i>ITGB4</i>	Del, Spl, MS
		<i>COL17A1</i>	MS
		<i>ITGB4</i>	NS, MS, Del, Spl, Ins, Indels
	JEB, late onset	<i>ITGA6</i>	Del, MS, NS, Spl
	JEB with pyloric atresia	<i>ITGA3</i>	MS, Del, Spl
	JEB with respiratory and renal involvement	<i>LAMA3A</i>	Ins, NS
JEB-LOC syndrome			
DEB	RDEB, severe generalized	<i>COL7A1</i>	NS, Del, Spl, Ins, Indels, MS
	RDEB, generalized and localized	<i>COL7A1</i>	MS, NS, Del, Spl, Ins, Indels
	DDEB (all subtypes)	<i>COL7A1</i>	MS, Spl, Del
Kindler syndrome	Kindler syndrome	<i>FERMT1 (KIND1)</i>	NS, Del, Spl, Ins, Indels

Del, Deletion; *DDEB*, dominant dystrophic epidermolysis bullosa; *DEB*, dystrophic epidermolysis bullosa; *EB*, epidermolysis bullosa; *EBS*, epidermolysis bullosa simplex; *Indels*, small deletion /insertion; *Ins*, insertion; *JEB*, junctional epidermolysis bullosa; *LOC*, laryngo-onycho-cutaneous; *MS*, missense mutation; *NS*, nonsense mutation; *RDEB*, recessive dystrophic epidermolysis bullosa; *Spl*, splice site mutation. In many cases with recessive inheritance, 2 different mutations are present in 1 individual (compound heterozygosity).

This table depicts the common mutation constellations, but it is not exhaustive (source: Human Gene Mutation Database Professional 2013.2 [<http://www.hgmd.cf.ac.uk/ac/index.php>]). For the sake of simplicity, some very rare mutation constellations have been excluded. Whenever possible, the order of the mutation types reflects their representation.

Of note, the new technologies of parallel sequencing using gene panels or exome sequencing allow screening for mutations in several genes at the same time. As they become more widely available and at lower cost, they will likely replace at least some of the candidate gene approaches for molecular genetic diagnosis of EB.

our clinical summary tables the most commonly used older names for each subtype, to facilitate linkage to the older literature. We realize that some clinicians may still choose to continue to use some of these older names. The changes that we are proposing in this consensus report are therefore only recommendations from a large group of experts, composed of both clinical and basic investigators, who see, study, and treat large numbers of patients with EB worldwide.

When some EB eponyms were eliminated in 2008, we used the term “generalized other” to encompass patients who had generalized disease activity but lacked the phenotypic and laboratory findings of those subclassified as having generalized severe disease. To clarify this and provide a less awkward name than “other,” those subtypes referred to as “generalized other” will be named “generalized

intermediate” to distinguish them from those with generalized severe disease activity. We also recommend elimination of the term “lethal” for patients with acantholytic EBS; although JEB Herlitz is oftentimes also fatal in infancy or early childhood, the same term used synonymously with it added little but increased anxiety to the parents of a newborn.

UPDATED SUMMARIES OF THE CLINICAL AND LABORATORY FINDINGS IN EB SUBTYPES

Tables X to XIII summarize the clinical findings on each of the major EB subtypes. Similar tables on the minor or rarer subtypes may be found in Tables XIV to XXVI. Although we have made every effort to ensure that the descriptions are correct for each subtype, we recognize that new clinical findings or associations may be reported in the future and that

Table VIII. Comparison of 2008 nomenclature with proposed “onion skin” terminology—representative examples

Old name (per 2008 recommendations)	2013 “onion skin” nomenclature
EBS, localized	EBS localized, normal keratin 5 and 14 staining, <i>KRT5</i> or <i>KRT14</i> mutation (specify type)
EBS, Dowling-Meara	EBS generalized severe, normal keratin 5 and 14 staining, <i>KRT5</i> or <i>KRT14</i> mutation (specify type)
EBS, generalized other	EBS generalized intermediate, normal keratin 5 and 14 staining, <i>KRT5</i> or <i>KRT14</i> mutation (specify type)
EBS-MP	EBS-MP, normal keratin 5 staining, <i>KRT5</i> mutation (specify type)
JEB, Herlitz	JEB generalized severe, laminin-332 absent, <i>LAMA3</i> , <i>LAMB3</i> , or <i>LAMC2</i> mutations (specify type)
JEB, non-Herlitz	JEB generalized intermediate, laminin-332 or collagen XVII reduced staining, <i>LAMA3</i> , <i>LAMB3</i> , <i>LAMC2</i> , or <i>COL17A1</i> mutations (specify type)
RDEB, generalized severe	RDEB generalized severe, collagen VII absent, <i>COL7A1</i> mutations (specify type)
RDEB, generalized other	RDEB generalized intermediate, collagen VII reduced staining, <i>COL7A1</i> mutations (specify type)
RDEB-BDN	RDEB-BDN, granular intraepidermal collagen VII staining, <i>COL7A1</i> mutations (specify)
DDEB generalized	DDEB generalized, normal collagen VII staining, <i>COL7A1</i> mutation (specify)

BDN, Bullous dermolysis of newborn; *DDEB*, dominant dystrophic epidermolysis bullosa; *EBS*, epidermolysis bullosa simplex; *JEB*, junctional epidermolysis bullosa; *MP*, mottled pigmentation; *RDEB*, recessive dystrophic epidermolysis bullosa.

differences exist even among those having the same EB subtype. Whenever possible, we have described those differing observations in footnotes in the tables. Sometimes striking differences in overall disease severity and/or clinical findings may be seen within a single kindred in whom the same mutation is present, the result of environmental or epigenetic factors, or the influence of modifying genes. Although these tables represent our best composite pictures of patients with EB within each major and minor subtype, some differences may be noted in individual patients. They should be used as guidelines when assessing a patient but not as absolute phenotypic criteria.

Table IX. Proposed names for epidermolysis bullosa subtypes previously associated with eponyms

Old name with associated eponym	New name
EBS, Weber-Cockayne	EBS, localized
EBS, Dowling-Meara	EBS, generalized severe
EBS, Koebner	EBS, generalized intermediate
JEB, Herlitz	JEB, generalized severe
JEB, non-Herlitz	JEB, generalized intermediate
DDEB, Cockayne-Touraine and Pasini	DDEB, generalized
RDEB, Hallopeau-Siemens	RDEB, generalized severe
RDEB, non-Hallopeau-Siemens	RDEB, generalized intermediate
Bart syndrome	EB with congenital absence of skin

DDEB, Dominant dystrophic epidermolysis bullosa; *EB*, epidermolysis bullosa; *EBS*, epidermolysis bullosa simplex; *JEB*, junctional epidermolysis bullosa; *RDEB*, recessive dystrophic epidermolysis bullosa.

OTHER REPORTED BUT NOT YET ADOPTED EB SUBTYPES

The recent literature contains several case reports, based on the findings in 1 or only a small number of patients, proposing the existence of other EB subtypes. We critically reviewed each of these reports and have incorporated as new entities those that presented sufficient documentation to merit inclusion at this time. Others must await more rigorous confirmation. As an example, 2 children reported as having pretibial EB and renal disease were shown to have mutations in the gene encoding for CD151, a member of the tetraspanin family known to be a component of the hemidesmosome.³ Our review of the available information failed to document sufficient electron microscopic and immunohistochemical data to allow us to confirm the precise level of blister formation within the skin BMZ that would permit us to distinguish between JEB and DEB, a major concern because pretibial EB is considered to be a subtype of DEB. More rigorous characterization will hopefully resolve this. A pedigree was reported of patients with vesicles resulting from a homozygous nonsense mutation in the *DSC3* gene, encoding the desmosomal glycoprotein desmocollin-3, but no definitive clinical or histopathologic evidence of blistering was presented; the clinical images showed hypotrichosis and keratosis pilaris and histopathology revealed mild follicular plugging only.^{4,5} To date, there is

Table X. Clinical summary of epidermolysis bullosa simplex localized, generalized severe, and generalized intermediate subtypes

	EBS, localized	EBS, generalized severe	EBS, generalized intermediate
Former eponyms or names	Weber-Cockayne	EBS, Dowling-Meara; EBS herpetiformis	EBS, generalized other; non-Dowling-Meara, EBS, Koebner
Mode of transmission	AD	AD	AD
Onset (usual)	Early childhood	Birth	Birth
Skin distribution (predominant)	Palms and soles	Generalized (with relative sparing of palms and soles)	Generalized
Skin findings (frequency*)			
Blisters	4+	4+	4+
Milia	Rare	1-2+	1+
Atrophic scarring	Rare	2+	1+
Dystrophic or absent nails	Uncommon	2+	1-2+
Granulation tissue	Absent	Absent	Absent
Scalp abnormalities	Absent	Absent	Absent
Keratoderma (palms and soles)	Focal (by adulthood in some)	Usually diffuse	Focal
Other	None	Arciform ("herpetiform") blistering; EB nevi (rare)	EB nevi (rare)
Relative inducibility of blisters	Common	Common	Common
Extracutaneous involvement*			
Anemia	Absent	Variable	Absent
Growth retardation	Absent	Common	Absent
Oral cavity			
Soft-tissue abnormalities	Erosions in about 25% in infancy	Common	Variable
Enamel hypoplasia	Absent	Absent	Absent
Caries	Normal frequency	Normal frequency	Normal frequency
Gastrointestinal tract	Absent	2+ (Constipation)	Absent
Genitourinary tract	Absent	Absent	Absent
Ocular	Absent	Absent	Rare
Pseudosyndactyly	Absent	Absent	Absent
Respiratory tract	Absent	Uncommon	Absent
Risk* by age 30 y of			
Squamous cell carcinoma	None	None	None
Malignant melanoma	None	None	Very rare
Basal cell carcinoma	None	None	None
Death related to EB	None	Uncommon	None

AD, Autosomal dominant; EB, epidermolysis bullosa; EBS, epidermolysis bullosa simplex.

*Relative frequencies: absent; rare; 1+; 2+; 3+; 4+.

insufficient tissue or other laboratory studies to adequately support the diagnosis of EB.

For inclusion into further revised classification schemes, any newly proposed EB subtype will need to have sufficient clinical, ultrastructural, immunohistochemical, and ideally molecular characterization to demonstrate that it is sufficiently different from previously described EB subtypes.

SUMMARY

This revised classification of EB incorporates several new genetic subtypes. Where possible we have replaced eponyms with descriptive terms. We

hope our proposed systematic onion skin approach using successive layers of clinical, immunohistochemical, and molecular findings will prove useful to both clinicians and researchers, and adaptable to future discoveries.

The authors wish to thank DEBRA International for its continued generous support of basic and clinical research and international EB conferences such as this, its many member DEBRA organizations, and our thousands of patients worldwide whose patience, loyalty, and cooperation over many decades have permitted collection of the data embraced by these consensus reports.

Table XI. Clinical summary of junctional epidermolysis bullosa generalized severe, generalized intermediate, and localized subtypes²⁰⁻²³

	JEB, generalized severe	JEB, generalized intermediate	JEB, localized
Eponyms or previous names	JEB, Herlitz	JEB, generalized non-Herlitz; JEB, generalized other; GABEB	None
Mode of transmission	AR	AR	AR
Onset (usual)	Birth	Birth	Birth
Skin distribution (predominant)	Generalized	Generalized	Localized
Skin findings (frequency*)			
Blisters	4+	3-4+	2+
Milia	2+	1-2+	1+
Atrophic scarring	3+	2-3+	Absent
Dystrophic or absent nails	4+	2-4+	4+
Granulation tissue	4+	Absent to rare	Absent
Scalp abnormalities	2+	Diffuse nonscarring or scarring alopecia	Absent
Keratoderma	Absent	Absent to focal +	Absent
Other	None	EB nevi	None
Relative inducibility of blisters	4+	2-4+	2+
Extracutaneous involvement*			
Anemia	4+	Absent -2+	Absent
Growth retardation	4+	Absent -2+	Absent
Oral cavity			
Soft-tissue abnormalities	4+	1-3+	1+
Enamel hypoplasia	4+ †	4+	4+
Caries	Excessive	Excessive	Excessive
Gastrointestinal tract	3+	Absent -2+ §	Absent
Genitourinary tract	2+	Absent -2+	Absent
Ocular	3+	Absent -2+	Absent
Pseudosyndactyly	1+	Absent §	Absent
Respiratory tract	3+	Absent -2+	Absent
Other	Delayed puberty	None §	None
Risk* by age 30 y of			
Squamous cell carcinoma	Uncommon	2+	None
Malignant melanoma	None	None	None
Basal cell carcinoma	None	None	None
Death related to EB	4+ ‡	1+ ‡	None

AR, Autosomal recessive; EB, epidermolysis bullosa; GABEB, generalized atrophic benign epidermolysis bullosa; JEB, junctional epidermolysis bullosa.

*Relative frequencies: absent or none; rare; 1+; 2+; 3+; 4+.

†Carriers with *LAMA3* null mutations have enamel defects.²² Similarly, a mouse model for JEB has demonstrated that *COL17A1* plays a key role in enamel formation.²³

‡Death occurs in about half of those with generalized severe JEB and generalized intermediate JEB within the first 2 y of life, with a further increase in the cumulative risk of death in the former JEB subtype with increasing age. Although there are a variety of causes of death in both JEB subtypes during infancy and early childhood, the most common ones are sepsis, upper airway occlusion, and failure-to-thrive, the latter primarily arising in generalized severe JEB.

§Rare patients have had pseudosyndactyly, protein losing enteropathy, profound failure to thrive, low birth weight, and/or early death.

||The cumulative lifetime risk of squamous cell carcinoma has been estimated to be 18% in JEB generalized severe (per National EB Registry data²⁰), whereas cross-sectional analysis of the Groningen, The Netherlands, JEB cohort has revealed the presence of these tumors in approximately 25% of those with generalized intermediate JEB.²¹

REFERENCES

1. Fine J-D, Eady RAJ, Bauer JA, Bauer JW, Bruckner-Tuderman L, Heagerty A, et al. The classification of inherited epidermolysis bullosa (EB): report of the third international consensus meeting on diagnosis and classification of EB. *J Am Acad Dermatol* 2008;58:931-50.
2. Pearson RW. Studies on the pathogenesis of epidermolysis bullosa. *J Invest Dermatol* 1962;39:551-75.
3. Karamatic Crew V, Burton N, Kagan A, Green CA, Levene C, Flinter F, et al. CD151, the first member of the tetraspan (TM4) superfamily detected on erythrocytes, is essential for the correct assembly of human basement membranes in kidney and skin. *Blood* 2004;104:2217-23.
4. Ayub M, Basit S, Jelani M, Ur Rehman F, Iqbal M, Yasinzai M, Ahmad W. A homozygous nonsense mutation in the human desmocollin-3 (DSC3) gene underlies hereditary

Table XII. Clinical summary of dominant dystrophic epidermolysis bullosa generalized, recessive dystrophic epidermolysis bullosa generalized severe, and recessive dystrophic epidermolysis bullosa generalized intermediate subtypes²⁰

	DDEB, generalized	RDEB, generalized severe	RDEB, generalized intermediate
Previous eponym or name	Pasini; Cockayne-Touraine	Hallopeau-Siemens	Non-Hallopeau-Siemens; RDEB, generalized other
Mode of transmission	AD	AR	AR
Onset (usual)	Birth	Birth	Birth
Skin distribution (predominant)	Generalized	Generalized	Generalized
Skin findings (frequency*)			
Blisters	2-3+	4+	3-4+
Milia	3+	4+	3-4+
Atrophic scarring	3-4+	4+	3-4+
Dystrophic or absent nails	4+	4+	4+
Granulation tissue	Absent	Common in chronic wounds	Uncommon
Scalp abnormalities	2+	3+	2+
Keratoderma	None	None	None
Other	"Albopapuloid lesions" (variable)	EB nevi	EB nevi
Relative inducibility of blisters	Variable	High	High
Extracutaneous involvement*			
Anemia	1+	4+	2+
Growth retardation	Rare	4+	2+
Oral cavity			
Soft-tissue abnormalities	3+	4+	3+
Enamel hypoplasia	Absent	Absent [§]	Absent
Caries	Normal frequency	Excessive	Increased frequency
Gastrointestinal tract	2+	4+	3-4+
Genitourinary tract	Rare	Uncommon	Rare
Ocular	1+	3+	2+
Pseudosyndactyly	Rare [†]	4+	Variable [†]
Respiratory tract	Absent	Absent	Absent
Other	Absent	Glomerulonephritis, renal amyloidosis; IgA nephropathy; CRF; cardiomyopathy; delayed puberty; osteoporosis	Absent
Risk* by age 30 y of			
Squamous cell carcinoma	None [‡]	3+	2+
Malignant melanoma	None	1+ [¶]	None
Basal cell carcinoma	None	None	None
Death related to EB	None	4+ [#]	2+ [#]

AD, Autosomal dominant; AR, autosomal recessive; CRF, chronic renal failure; DDEB, dominant dystrophic epidermolysis bullosa; EB, epidermolysis bullosa; RDEB, recessive dystrophic epidermolysis bullosa.

*Relative frequencies: absent; rare; 1+; 2+; 3+; 4+.

[†]When present, the digital webbing is usually localized or partial, as contrasted with RDEB generalized severe, where the deformities are usually bilateral and severe, with eventual fusion of all digits, marked flexion contractures, and bony resorption.

[‡]Per data from the US National EB Registry.²⁰

[§]Of note, enamel abnormalities have been recently observed via scanning electron microscopy in the teeth in a murine model for RDEB generalized severe. Although not as yet documented at the clinical level in human beings, as they have in junctional EB teeth, such microscopic defects may explain the propensity of these patients for developing severe caries during early childhood.

^{||}Although rare cases have been reported to occur at an earlier age, data from the US National EB Registry have shown that the cumulative risk of cutaneous squamous cell carcinomas arising in generalized severe and generalized intermediate RDEB subtypes usually begins during the mid to late teenage years and then increases thereafter, strikingly so in the former RDEB subtype, with death from metastases from squamous cell cancer occurring in the majority of those with generalized severe RDEB within the first 5 y after diagnosis and surgical removal of the first primary tumor.

[¶]Documented rarely by age 12 y in this RDEB subtype, and with no further increased cumulative risk thereafter.

[#]With the exception of rare cases succumbing to sepsis during infancy, the risk of premature death in patients with generalized severe and intermediate subtypes of RDEB is most often a result of metastatic squamous cell carcinoma in young adulthood or later life. Death may also result from CRF in a small minority of these patients.

Table XIII. Clinical summary of Kindler syndrome²⁴

Kindler syndrome ²⁴	
Mode of transmission	AR
Onset	Birth
Skin distribution (predominant)	Generalized
Skin findings (frequency*)	
Blisters	3+, Childhood; 1+, adults
Milia	Rare –1+
Atrophic scarring	3+
Dystrophic or absent nails	2+
Granulation tissue	1+
Keratoderma	Present
Other	Poikiloderma; photosensitivity; skin atrophy; bone abnormalities (rare)
Relative inducibility of blisters	Variable
Extracutaneous involvement*	
Anemia	Occasional
Growth retardation	Absent
Oral cavity	
Soft-tissue abnormalities	Common; gingival hyperplasia
Enamel hypoplasia	Absent
Caries	Increased frequency
Gastrointestinal tract	Colitis (may be severe); esophagitis and esophageal strictures
Genitourinary tract	1+ (Urethral strictures)
Ocular	Ectropion
Pseudosyndactyly (or digital tapering)	2+
Respiratory tract	Absent
Risk* of	
Squamous cell carcinoma	Increased (after age 30 y)
Malignant melanoma	None
Basal cell carcinoma	None
Death related to Kindler syndrome	Uncommon

AR, Autosomal recessive.

*Scale: absent or none; rare; 1+; 2+; 3+; 4+.

hypotrichosis and recurrent skin vesicles. *Am J Hum Genet* 2009;85:515-20.

- Payne AS. No evidence of skin blisters with human desmocollin-3 gene mutation. *Am J Hum Genet* 2010;86:292.
- Blaydon DC, Nitoiu D, Eckl KM, Cabral RM, Bland P, Hausser I, et al. Mutations in *CSTA*, encoding cystatin A, underlie exfoliative ichthyosis and reveal a role for this protease inhibitor in cell-cell adhesion. *Am J Hum Genet* 2011;89:564-71.
- Kronic AL, Stone KL, Simpson MA, McGrath JA. Acral peeling skin syndrome resulting from a homozygous nonsense mutation in the *CSTA* gene encoding cystatin A. *Pediatr Dermatol* 2013;30:e87-8.
- Cabral RM, Kurban M, Wajid M, Shimomura Y, Petukhova L, Christiano AM. Whole-exome sequencing in a single proband

Table XIV. Clinical summary of acral peeling skin syndrome¹⁰

APSS ¹⁰	
Mode of transmission	AR
Onset	Infancy or early childhood
Skin distribution (predominant)	Hands and feet (ventral and dorsal aspects)
Skin findings (frequency*)	
Blisters or erosions	Rare erosions [‡]
Milia	Absent
Atrophic scarring	Absent
Dystrophic or absent nails	Absent
Granulation tissue	Absent
Keratoderma	Absent [‡]
Other	Cutaneous peeling
Relative inducibility of blisters	Variable, worse in warm and humid environment
Extracutaneous involvement*	Absent
Anemia	Absent
Growth retardation	Absent
Oral cavity	
Soft-tissue abnormalities	Rare erosions [‡]
Enamel hypoplasia	Absent
Caries	Absent
Gastrointestinal tract	Absent
Genitourinary tract	Absent
Ocular	Absent
Pseudosyndactyly	Absent
Respiratory tract	Absent
Risk* by age 30 y of	
Squamous cell carcinoma	None
Malignant melanoma	None
Basal cell carcinoma	None
Death related to EB	None

APSS, Acral peeling skin syndrome; AR, autosomal recessive; EB, epidermolysis bullosa.

*Relative frequencies: absent; rare; 1+; 2+; 3+; 4+.

[†]Based on findings in 27 patients within the originally described cohort from Freiburg, Germany, and confirmed in other patients seen elsewhere. This EB simplex subtype accounted for the majority of patients with EB simplex being followed up in Freiburg, Germany, who lacked *KRT5* or *KRT14* mutations, emphasizing how common this entity is.

[‡]Oral blisters and keratoderma have been seen in a few patients in the London APSS cohort. Within the same patient population, 2+ cutaneous blistering was also observed.

reveals a mutation in the *CHST8* gene in autosomal recessive peeling skin syndrome. *Genomics* 2012;99:202-8.

- Wilson NJ, Messenger AG, Leachman SA, O'Toole EA, Lane EB, McLean WH, Smith FJ. Keratin K6c mutations cause focal palmoplantar keratoderma. *J Invest Dermatol* 2010;130:425-9.
- Kiriti D, Cosgarea I, Franzke CW, Schumann H, Oji V, Kohlhase J, et al. Acral peeling skin syndrome with *TGM5* gene mutations may resemble epidermolysis bullosa simplex in young individuals. *J Invest Dermatol* 2010;130:1741-6.
- Jonkman JF, Pasmooij AM, Pasmans SG, van den Berg MP, Ter Horst HJ, Timmer A, Pas HH. Loss of desmoplakin tail

Table XV. Clinical summary of epidermolysis bullosa simplex superficialis and acantholytic epidermolysis bullosa simplex¹¹⁻¹⁴

	EBS superficialis [†]	Acantholytic EBS (DSP mutations ¹¹⁻¹³)	Acantholytic EBS (JUP mutations ¹⁴)
Mode of transmission	Unknown	AR	AR
Onset (usual)	Birth	Birth	Birth
Skin distribution (predominant)	Generalized	Generalized	Generalized
Skin findings (frequency*)			
Blisters	Superficial erosions, not blisters	Oozing erosions, not blisters	Oozing erosions, not blisters
Milia	Absent	Absent	Absent
Atrophic scarring	Absent	Absent	Absent
Dystrophic or absent nails	Absent	4+	4+
Granulation tissue	Absent	Absent	Absent
Scalp abnormalities	Absent	Alopecia	Alopecia
Keratoderma	Absent	Absent	Absent
Other	Postinflammatory hypopigmentation	Neonatal teeth	Infection
Relative inducibility of blisters	Sheetlike removal	Sheetlike removal	Sheetlike removal
Extracutaneous involvement*			
Anemia	Rare	Absent	Yes
Growth retardation	Absent	Absent	Absent
Oral cavity			
Soft-tissue abnormalities	None	Erosions	None
Enamel hypoplasia	None	None	Absent
Caries	Normal frequency	None	None
Gastrointestinal tract	Absent	Present	Absent
Genitourinary tract	Absent	Present	Absent
Ocular	Absent	Absent	Absent
Pseudosyndactyly	Absent	Absent	Absent
Respiratory tract	Absent	Present	Absent
Other	Absent	Cardiomyopathy	Infections
Risk* by age 30 y of			
Squamous cell carcinoma	None	None	None
Malignant melanoma	None	None	None
Basal cell carcinoma	None	None	None
Death (all causes)	None	Present [‡]	Present [‡]

AR, Autosomal recessive; EBS, epidermolysis bullosa simplex.

*Scale: absent or none; rare; 1+; 2+; 3+; 4+.

[†]Based on the findings seen in the original well-characterized proband; subsequently, the other autosomal dominant kindred was proven to have dominant dystrophic epidermolysis bullosa.

[‡]Death usually occurs in children with acantholytic EBS in the neonatal period. As such, the possibility of the occurrence of extracutaneous complications (eg, anemia) typically seen in older children with some severe epidermolysis bullosa subtypes cannot be fully excluded, were a child to survive for several years, because only limited numbers of cases with this rare subtype have been reported.

- causes lethal acantholytic epidermolysis bullosa. *Am J Hum Genet* 2005;77:653-60.
- Hobbs RP, Han SY, van der Zwaag PA, Bolling MC, Jongbloed JD, Jonkman MF, et al. Insights from a desmoplakin mutation identified in lethal acantholytic epidermolysis bullosa. *J Invest Dermatol* 2010;130:2680-3.
 - Bolling MC, Veenstra MJ, Jonkman MF, Diercks GF, Curry CJ, Fisher J, et al. Lethal acantholytic epidermolysis bullosa due to a novel homozygous deletion in DSP: expanding the phenotype and implications for desmoplakin function in skin and heart. *Br J Dermatol* 2010;162:1388-94.
 - Pigors M, Kiritsi D, Krumpelmann S, Wagner N, He Y, Podda M, et al. Lack of plakoglobin leads to lethal congenital epidermolysis bullosa: a novel clinico-genetic entity. *Hum Mol Genet* 2011;20:1811-9.
 - Pigors M, Kiritsi D, Cobzaru C, Schwieger-Briel A, Suárez J, Faletra F, et al. TGM5 mutations impact epidermal differentiation in acral peeling skin syndrome. *J Invest Dermatol* 2012;132:2422-9.
 - McGrath JA, Mellerio JE. Ectodermal dysplasia-skin fragility syndrome. *Dermatol Clin* 2010;28:125-9.
 - McGrath JA, Stone KL, Begum R, Simpson MA, Dopping-Hepenstal PJ, Liu L, et al. Germline mutation in EXPH5 implicates the Rab27B effector protein Slac2-b in inherited skin fragility. *Am J Hum Genet* 2012;91:1115-21.
 - Pigors M, Schwieger-Briel A, Leppert J, Kiritsi D, Kohlhase J, Bruckner-Tuderman L, et al. Molecular heterogeneity of epidermolysis bullosa simplex: contribution of EXPH5 mutations. *J Invest Dermatol* 2014;134:842-5.
 - Groves RW, Liu L, Dopping-Hepenstal PJ, Markus HS, Lovell PA, Ozoemena L, et al. A homogeneous nonsense mutation within

Table XVI. Clinical summary of epidermolysis bullosa simplex skin fragility syndromes^{16,25,26}

	Skin fragility-woolly hair syndrome (<i>DSP</i> mutations ²⁵)	Skin fragility-ectodermal dysplasia syndrome (<i>PKP1</i> mutations)	Skin fragility, plakoglobin deficiency (<i>JUP</i> mutations ²⁶)
Mode of transmission	AR	AR	AR
Onset (usual)	Birth or early infancy	Birth	Birth
Skin distribution (predominant)	Generalized	Generalized	Generalized
Skin findings (frequency*)			
Blisters	Superficial erosions and crusts, not blisters	Superficial erosions and crusts; blisters less common	2+ Erosions
Milia	Absent [†]	Absent	Absent
Atrophic scarring	Absent [†]	Absent	Absent
Dystrophic or absent nails	2+	4+	4+
Granulation tissue	Absent	Absent	Absent
Scalp abnormalities	Hypotrichosis, woolly hair	Hypotrichosis, woolly hair	Hypotrichosis, woolly hair
Keratoderma	Focal, punctate or striate, with fissuring	Focal, with fissuring	Focal, with fissuring
Other	Follicular hyperkeratosis over extensors	Perioral fissuring; circinate scaly erosions	
Relative inducibility of blisters	Variable	Variable	Variable
Extracutaneous involvement*			
Anemia	1+	Absent	Absent
Growth retardation	1+	2+	Absent
Oral cavity			
Soft-tissue abnormalities	Erosions	Tongue fissuring	Absent
Enamel hypoplasia	None	Absent	Absent
Caries	Normal frequency	Normal frequency	Normal frequency
Gastrointestinal tract	Absent	Constipation	Absent
Genitourinary tract	Absent	Absent	Absent
Ocular	‡	‡	Absent
Pseudosyndactyly	Absent	Absent	Absent
Respiratory tract	Rarely hoarseness, stridor	Absent	Absent
Other	Cardiomyopathy	Absent	?Cardiomyopathy
Risk* by age 30 y of			
Squamous cell carcinoma	None	None	None
Malignant melanoma	None	None	None
Basal cell carcinoma	None	None	None
Death (all causes)	Unknown [§]	Unknown	Unknown [§]

AR, Autosomal recessive; †, there is some disagreement about whether those specific findings are correct as previously reported in the literature.

*Scale: absent or none; rare; 1+; 2+; 3+; 4+.

[†]Milia and atrophic scarring arose in an area of aplasia cutis on the ankle of 1 affected individual (Jemima Mellerio, MD, FRCP, personal written communication, 2013).

[‡]Blepharitis; absent or sparse eyelashes.

[§]Development of cardiomyopathy might be progressive and lead to death but most reported cases are still children.

^{||}Esophageal stricture in 1 patient.

- the dystonin gene coding for the coiled-coil domain of the epithelial isoform of BPAG1 underlies a new subtype of autosomal recessive epidermolysis bullosa simplex. *J Invest Dermatol* 2010;130:1551-7.
- Fine J-D, Johnson LB, Weiner M, Li K-P, Suchindran C. Inherited epidermolysis bullosa (EB) and the risk of life-threatening skin-derived cancers: experience of the National EB Registry, 1986-2006. *J Am Acad Dermatol* 2009;60:203-11.
 - Yuen WY, Jonkman MF. Risk of squamous cell carcinoma in junctional epidermolysis bullosa, non-Herlitz type: report of 7 cases and a review of the literature. *J Am Acad Dermatol* 2011;65:780-9.
 - Yuen WY, Pasmooij AMG, Stellingsma C, Jonkman MF. Enamel defects in carriers of a novel LAMA3 mutation underlying epidermolysis bullosa. *Acta Derm Venereol* 2012;92:695-6.
 - Asaka T, Akiyama M, Doman T, Nishie W, Natsuga K, Fujita Y, et al. Type XVII collagen is a key player in tooth enamel formation. *Am J Pathol* 2009;174:91-100.
 - Has C, Castiglia D, del Rio M, Diez MG, Piccinni E, Kiritsi D, et al. Kindler syndrome: extension of FERMT1 mutational spectrum and natural history. *Hum Mutat* 2011;32:1204-12.
 - Smith FJ, Wilson NJ, Moss C, Dopping-Hepenstal P, McGrath J. Compound heterozygous mutations in desmoplakin cause skin fragility and woolly hair. *Br J Dermatol* 2012;166:894-6.

Table XVII. Clinical summary of autosomal recessive epidermolysis bullosa simplex-K14, -Ogna, and -migratory circinate subtypes^{27,28}

	AR EBS-K14	EBS-Ogna	EBS-migratory circinate
Mode of transmission	AR	AD	AD
Onset (usual)	Birth	Birth	Birth
Skin distribution (predominant)	Generalized; anogenital	Mainly acral; may be widespread	Generalized
Skin findings (frequency*)			
Blisters	3+	3+	4+
Milia	Rare	Absent	Absent
Atrophic scarring	1+	Absent	Absent
Dystrophic or absent nails	2+	Onychogryphosis	1+
Granulation tissue	Absent	Absent	Absent
Scalp abnormalities	Absent	Absent	Absent
Keratoderma (palms and soles)	Focal	Absent	Absent
Other	Ichthyotic plaques; EB nevi (rare)	? Tendency to bruise [†]	Migratory circinate erythema; brown postinflammatory hyperpigmentation
Relative inducibility of blisters	3+	2+	Variable
Extracutaneous involvement*			
Anemia	1+	Absent	Absent
Growth retardation	2+	Absent	Absent
Oral cavity			
Soft-tissue abnormalities	3+	Absent	Absent
Enamel hypoplasia	Absent	Absent	Absent
Caries	1+	Normal frequency	Normal frequency
Gastrointestinal tract	2+ (Constipation)	Absent	Absent
Genitourinary tract	1+	Absent	Absent
Ocular	Absent	Absent	Absent
Pseudosyndactyly	Absent	Absent	Absent
Respiratory tract	Absent	Absent	Absent
Risk* by age 30 y of			
Squamous cell carcinoma	None	None	None
Malignant melanoma	None	None	None
Basal cell carcinoma	None	None	None
Death related to EB	None	None	None

AD, Autosomal dominant; AR, autosomal recessive; EB, epidermolysis bullosa; EBS, epidermolysis bullosa simplex; ?, there is some disagreement about whether those specific findings are correct as previously reported in the literature.

*Relative frequencies: absent; rare; 1+; 2+; 3+; 4+.

[†]Although historically patients with EBS-Ogna were reported to have a tendency for easy bruising, this has not been confirmed by several other groups more recently, suggesting the possibility that this may not be a valid phenotypic marker of this disease but rather just an unrelated incidental finding.

26. Cabral RM, Liu L, Hogan C, Dopping-Hepenstal PJ, Winik BC, Asial RA, et al. Homozygous mutations in the 5' region of the JUP gene result in cutaneous disease but normal heart development in children. *J Invest Dermatol* 2010;130:1543-50.
27. Yiasemides E, Trisnowati N, Su J, Dang N, Klingberg S, Marr P, et al. Clinical heterogeneity in recessive epidermolysis bullosa due to mutations in the keratin 14 gene, KRT14. *Clin Exp Dermatol* 2008;33:689-97.
28. Kiritsi D, Pigors M, Tantcheva-Poor I, Wessel C, Arin MJ, Kohlhasse J, et al. Epidermolysis bullosa simplex Ogna revisited. *J Invest Dermatol* 2013;133:270-3.
29. Dang N, Klingberg S, Rubin AI, Edwards M, Borelli S, Relic J, et al. Differential expression of pyloric atresia in junctional epidermolysis bullosa with ITGB4 mutations suggests that pyloric atresia is due to factors other than the mutations and not predictive of a poor outcome: three novel mutations and review of the literature. *Acta Derm Venereol* 2008; 88:438-48.
30. Yuen WY, Pas HH, Sinke RJ, Jonkman MF. Junctional epidermolysis bullosa of late onset explained by mutations in COL17A1. *Br J Dermatol* 2011;164:1280-4.
31. Has C, Sparta G, Kiritsi D, Weibel L, Moeller A, Vega-Warner V, et al. Integrin alpha3 mutations with kidney, lung, and skin disease. *N Engl J Med* 2012;366:1508-14.
32. Nicolaou N, Margadant C, Kevelam SH, Lilien MR, Oosterveld MJ, Kreft M, et al. Gain of glycosylation in integrin alpha3 causes lung disease and nephrotic syndrome. *J Clin Invest* 2012;122: 4375-87.

Table XVIII. Clinical summary of epidermolysis bullosa simplex with mottled pigmentation, muscular dystrophy, and pyloric atresia subtypes

	EBS with mottled pigmentation	EBS with muscular dystrophy	EBS with pyloric atresia
Mode of transmission	AD	AR	AR
Onset (usual)	Birth	Blisters as early as birth; acral predominance; muscular dystrophy in infancy to adulthood	Birth
Skin distribution (predominant)	Generalized	Generalized	Generalized
Skin findings (frequency*)			
Blisters	4+	4+	4+
Milia	Rare	2+	Absent
Atrophic scarring	Absent	2-3+	2-3+
Dystrophic or absent nails	1+	4+	Absent
Granulation tissue	Absent	Absent	Absent
Scalp abnormalities	Absent	Absent	Absent
Keratoderma (palms and soles)	1+ Focal	Punctate or focal	Absent
Other	Mottled or reticulate brown pigmentation	None	Widespread congenital absence of skin
Relative inducibility of blisters	Variable	Variable	Common
Extracutaneous involvement*			
Anemia	Absent	1+	3+
Growth retardation	Absent	1+	3+
Oral cavity			
Soft-tissue abnormalities	Absent	1-2+	3+
Enamel hypoplasia	Absent	1-2+	Absent
Caries	Normal frequency	Normal frequency	Normal frequency
Gastrointestinal tract	Absent	Rare	4+ (Pyloric atresia)
Genitourinary tract	Absent	Rare	Absent
Ocular	Absent	Ptosis	Absent
Pseudosyndactyly	Absent	Absent	Absent
Respiratory tract	Absent	2+ (Granulation tissue/stenosis)	Absent
Other	Absent	Muscular dystrophy	Malformed pinnae and nasal alae; joint contractures; cryptorchidism
Risk* by age 30 y of			
Squamous cell carcinoma	None	None	None
Malignant melanoma	None	None	None
Basal cell carcinoma	None	None	None
Death related to EB	None	1-2+	3+

AD, Autosomal dominant; AR, autosomal recessive; EB, epidermolysis bullosa; EBS, epidermolysis bullosa simplex.

*Relative frequencies: absent or none; rare; 1+; 2+; 3+; 4+.

Table XIX. Clinical summary of autosomal recessive epidermolysis bullosa simplex BP230 deficiency subtype¹⁹

EBS, BP230 deficiency	
Mode of transmission	AR
Onset	Birth or childhood
Skin distribution (predominant)	Acral
Skin findings	
Blisters	2+
Milia	Absent
Atrophic scarring	Absent
Dystrophic or absent nails	1+
Granulation tissue	Absent
Keratoderma	Absent
Other	None
Relative inducibility of blisters	Mild
Extracutaneous involvement* [†]	
Anemia	Absent
Growth retardation	Absent
Oral cavity	
Soft-tissue abnormalities	Absent
Enamel hypoplasia	Absent
Caries	Normal frequency
Gastrointestinal tract	Absent
Genitourinary tract	Absent
Ocular	Absent
Pseudosyndactyly	Absent
Respiratory tract	Absent
Other	+
Risk by age 30 y of	
Squamous cell carcinoma	Unknown
Malignant melanoma	Unknown
Basal cell carcinoma	Unknown
Death related to EB	Unknown

AR, Autosomal recessive; EB, epidermolysis bullosa; EBS, epidermolysis bullosa simplex.

*Relative frequencies: absent; rare; 1+; 2+; 3+; 4+.

[†]A reported case had neurologic symptoms that may be attributable to co-existing CADASIL (cerebral autosomal dominant arteriopathy with subcortical infarcts and leukoencephalopathy) syndrome.

Table XX. Clinical summary of epidermolysis bullosa simplex exophilin 5 deficiency

EBS, exophilin 5 deficiency	
Mode of transmission	AR
Onset	Birth or infancy
Skin distribution (predominant)	Generalized
Skin findings*	
Blisters	Crusts, blisters
Milia	Absent
Atrophic scarring	Absent
Dystrophic or absent nails	Absent
Granulation tissue	Absent
Keratoderma	Absent
Other	Mild mottled pigmentary changes
Relative inducibility of blisters	Mild
Extracutaneous involvement*	
Anemia	Absent
Growth retardation	Absent
Oral cavity	
Soft-tissue abnormalities	Absent
Enamel hypoplasia	Absent
Caries	Normal frequency
Gastrointestinal tract	Absent
Genitourinary tract	Absent
Ocular	Absent
Pseudosyndactyly	Absent
Respiratory tract	Absent
Risk by age 30 y of*	
Squamous cell carcinoma	Unknown
Malignant melanoma	Unknown
Basal cell carcinoma	Unknown
Death related to EB	Unknown

AR, Autosomal recessive; EB, epidermolysis bullosa; EBS, epidermolysis bullosa simplex.

*Relative frequencies: absent; rare; 1+; 2+; 3+; 4+.

Table XXI. Clinical summary of junctional epidermolysis bullosa with pyloric atresia and junctional epidermolysis bullosa inversa subtypes²⁹

	JEB with pyloric atresia	JEB, inversa
Mode of transmission	AR	AR
Onset	Birth	Birth
Skin distribution (predominant)	Generalized	Intertriginous
Skin findings (frequency*)		
Blisters	4+	3+
Milia	1+	1+
Atrophic scarring	3+	3+
Dystrophic or absent nails	3+	3+
Granulation tissue	Absent	Absent
Keratoderma	Absent	Absent
Other	May be associated with large areas of aplasia cutis	None
Relative inducibility of blisters	Common	Common
Extracutaneous involvement*		
Anemia	Variable	Absent
Growth retardation	Variable	Absent
Oral cavity		
Soft-tissue abnormalities	Variable	Variable
Enamel hypoplasia	Present	Present
Caries	Excessive	Increased frequency
Gastrointestinal tract	4+ (Pyloric, duodenal, or anal atresia)	2+
GU tract	Multiple congenital GU malformations; acquired GU abnormalities [†]	Absent
Ocular	Variable	Unknown
Pseudosyndactyly	Absent	Absent
Respiratory tract	Absent	Absent
Other	Rudimentary ears	None
Risk by age 30 y of		
Squamous cell carcinoma	None	None
Malignant melanoma	None	None
Basal cell carcinoma	None	None
Death related to EB	4+	None

There are rare patients with JEB and integrin $\alpha 6$ or $\beta 4$ mutations who lack pyloric atresia.²⁹

AR, Autosomal recessive; EB, epidermolysis bullosa; GU, genitourinary; JEB, junctional epidermolysis bullosa.

*Relative frequencies: absent or none; rare; 1+; 2+; 3+; 4+.

[†]Polypoid bladder wall lesions; hemorrhagic cystitis; urethral strictures.

Table XXII. Clinical summary of junctional epidermolysis bullosa, late onset, and junctional epidermolysis bullosa—laryngo-onycho-cutaneous syndrome subtypes³⁰

	JEB, late onset ³⁰	JEB-LOC syndrome
Mode of transmission	AR	AR
Onset	Young adulthood or later	Birth
Skin distribution (predominant)	Variable	Especially facial and neck
Skin findings (frequency*)		
Blisters	4+	2+, with Erosions
Milia	4+	1+
Atrophic scarring	2+	2+
Dystrophic or absent nails	2+	4+
Granulation tissue	Absent	3+
Keratoderma	Mild	Absent
Other	Hyperhidrosis; absent dermatoglyphs	Increased incidence in Punjab
Relative inducibility of blisters*	Variable	1+
Extracutaneous involvement*		
Anemia	Absent	1+
Growth retardation	Absent	1+
Oral cavity		
Soft-tissue abnormalities	Variable	4+ Larynx
Enamel hypoplasia	Present	3+
Caries	Normal frequency	2+
Gastrointestinal tract	Absent	Absent
Genitourinary tract	Absent	1+
Ocular	Absent	4+ Conjunctival; eyelid granulomas; symblepharon
Pseudosyndactyly	Absent	Absent
Respiratory tract	Absent	4+
Risk* by age 30 y of		
Squamous cell carcinoma	None	None
Malignant melanoma	None	None
Basal cell carcinoma	None	None
Death related to EB	None	Common

AR, Autosomal recessive; EB, epidermolysis bullosa; JEB, junctional epidermolysis bullosa; LOC, laryngo-onycho-cutaneous.

*Scale: absent; rare; 1+; 2+; 3+; 4+.

Table XXIII. Clinical summary of junctional epidermolysis bullosa with respiratory and renal involvement subtype^{31,32}

	JEB with respiratory and renal involvement
Mode of transmission	AR
Onset	Respiratory and renal involvement at or shortly after birth; skin features within the first months of life
Skin distribution (predominant)	Legs, buttocks
Skin findings*	
Blisters	2+
Milia	Absent
Atrophic scarring	Absent
Dystrophic or absent nails	2+
Granulation tissue	Absent
Keratoderma	Absent
Other	Erosions 1+
Relative inducibility of blisters	Variable
Extracutaneous involvement*	
Anemia	4+
Growth retardation	4+
Oral cavity	
Soft-tissue abnormalities	Absent
Enamel hypoplasia	Not applicable
Caries	Not applicable
Gastrointestinal tract	Absent
Renal and genitourinary tract	Congenital nephrotic syndrome
Ocular	Absent
Pseudosyndactyly	Absent
Respiratory tract	Severe respiratory distress, interstitial pneumopathy
Risk* by age 30 y of	
Squamous cell carcinoma	Not applicable
Malignant melanoma	Not applicable
Basal cell carcinoma	Not applicable
Death related to EB	Within the first months of life

AR, Autosomal recessive; EB, epidermolysis bullosa; JEB, junctional epidermolysis bullosa.

*Relative frequencies: absent; rare; 1+; 2+; 3+; 4+.

Table XXIV. Clinical summary of dominant dystrophic epidermolysis bullosa localized, recessive dystrophic epidermolysis bullosa localized, dominant dystrophic epidermolysis bullosa pretibial, recessive dystrophic epidermolysis bullosa pretibial, and dystrophic epidermolysis bullosa pruriginosa subtypes

	DDEB, localized, and RDEB, localized	DDEB, pretibial, and RDEB, pretibial	DEB, pruriginosa
Mode of transmission	AD or AR	AD or AR	AD or AR
Onset (usual)	Birth or infancy	Birth or infancy	Variable from infancy to adulthood
Skin distribution (predominant)	Hands and feet	Pretibial; hands and feet; nails (fingers and toes)	Generalized or localized
Skin findings (frequency*)			
Blisters	4+	4+	4+
Milia	4+	4+	4+
Atrophic scarring	4+	4+	4+
Dystrophic or absent nails	3+	4+	4+
Granulation tissue	Absent	Absent	Absent
Scalp abnormalities	Absent	Absent	Absent
Keratoderma	Rare (striate)	Absent	Absent
Other	None	Lichenoid papules or plaques, or atrophic plaques	Severe pruritus
Relative inducibility of blisters	Variable	Variable	Variable
Extracutaneous involvement*			
Anemia	Absent	Absent	Rare
Growth retardation	Absent	Absent	Rare
Oral cavity			
Soft-tissue abnormalities	1+	1+	1+
Enamel hypoplasia	Absent	Absent	Absent
Caries	Normal frequency	Normal frequency	Normal frequency
Gastrointestinal tract	Absent	Absent	Absent
Genitourinary tract	Absent	Absent	Absent
Ocular	1+	1+	1+
Pseudosyndactyly	Absent	Absent	Absent
Respiratory tract	Absent	Absent	Absent
Risk* by age 30 y of			
Squamous cell carcinoma	None [†]	1+	1+
Malignant melanoma	None	None	None
Basal cell carcinoma	None	None	None
Death related to EB	None	None	None

AD, Autosomal dominant; AR, autosomal recessive; DDEB, dominant dystrophic epidermolysis bullosa; DEB, dystrophic epidermolysis bullosa; EB, epidermolysis bullosa; RDEB, recessive dystrophic epidermolysis bullosa.

*Relative frequencies: absent; rare; 1+; 2+; 3+; 4+.

[†]There may be an increased risk of squamous cell carcinoma at age >30 y.

Table XXV. Clinical summary of dominant dystrophic epidermolysis bullosa localized, nails only, and dystrophic epidermolysis bullosa—bullous dermolysis of the newborn subtypes

	DDEB, localized, nails only	DEB-BDN
Mode of transmission	AD	AD or AR
Onset (usual)	Childhood [†]	Birth or infancy
Skin distribution (predominant)	Nails only	Generalized
Skin findings (frequency*)		
Blisters	Absent	2-3+
Milia	Absent	2-3+
Atrophic scarring	Absent	2-3+
Dystrophic or absent nails	4+	2+
Granulation tissue	Absent	Absent
Scalp abnormalities	Absent	Absent
Keratoderma	Absent	Absent
Other	None	None
Relative inducibility of blisters	None	Variable
Extracutaneous involvement*		
Anemia	Absent	Absent
Growth retardation	Absent	Absent
Oral cavity		
Soft-tissue abnormalities	Absent	1+
Enamel hypoplasia	Absent	Absent
Caries	Normal frequency	Normal frequency
Gastrointestinal tract	Absent	Absent
Genitourinary tract	Absent	Absent
Ocular	Absent	Absent
Pseudosyndactyly	Absent	Absent
Respiratory tract	Absent	Absent
Risk* by age 30 y of		
Squamous cell carcinoma	None	None
Malignant melanoma	None	None
Basal cell carcinoma	None	None
Death related to EB	None	None

AD, Autosomal dominant; AR, autosomal recessive; BDN, bullous dermolysis of the newborn; DDEB, dominant dystrophic epidermolysis bullosa; DEB, dystrophic epidermolysis bullosa; EB, epidermolysis bullosa.

*Relative frequencies: absent; rare; 1+; 2+; 3+; 4+.

[†]Careful examination may reveal evidence of the patient having had preceding localized loss of skin, characterized by the presence of skin atrophy overlying the foot, shin, or ankle.

Table XXVI. Clinical summary of recessive dystrophic epidermolysis bullosa inversa and centripetalis subtypes

	RDEB, inversa	RDEB, centripetalis
Mode of transmission	AR	AR
Onset (usual)	Birth	Birth or infancy
Skin distribution (predominant)	Intertriginous; acral; lumbosacral; axial	Pretibial; nails (fingers and toes)
Skin findings (frequency*)		
Blisters	3+	3+
Milia	3-4+	3+
Atrophic scarring	3-4+	3+
Dystrophic or absent nails	4+	4+
Granulation tissue	Absent	Absent
Scalp abnormalities	Absent	Absent
Keratoderma	Absent	Absent
Other	None	None
Relative inducibility of blisters	Common	Common
Extracutaneous involvement*		
Anemia	2+	Absent
Growth retardation	2+	Absent
Oral cavity		
Soft-tissue abnormalities	4+	2+
Enamel hypoplasia	Absent	Absent
Caries	Increased	Normal frequency
Gastrointestinal tract	4+	Absent
Genitourinary tract	4+ [†]	Absent
Ocular	Absent	Absent
Pseudosyndactyly	1+	Absent
Respiratory tract	Absent	Absent
Other	External auditory canal stenosis	None
Risk* by age 30 y of		
Squamous cell carcinoma	None	None
Malignant melanoma	None	None
Basal cell carcinoma	None	None
Death related to EB	None	None

AR, Autosomal recessive; EB, epidermolysis bullosa; RDEB, recessive dystrophic epidermolysis bullosa.

*Relative frequencies: absent or none; rare; 1+; 2+; 3+; 4+.

[†]Severe vulvovaginal nonhealing erosions, blisters, strictures.